

Unusual case of tachycardia termination: what is the mechanism?

Ahmed T. Moustafa¹, Paul Purves², and George J. Klein¹

¹London Health Sciences Centre University Hospital

²St Mary's General Hospital Foundation

June 19, 2023

Abstract

Case: A 41-year-old man with no prior cardiac history and a history of regular narrow QRS tachycardia, presenting with frequent paroxysmal palpitations, was referred to our institution. The tachycardia was adenosine-sensitive, leading to the acute termination of the tachycardia. The baseline electrocardiogram was unremarkable. During an electrophysiology study (EPS), supraventricular tachycardia (SVT) was easily induced by ventricular extrastimuli. Figure [1](#fig-cap-0003) shows a single ventricular extrastimulus applied from the right ventricular apex (RVa) during the tachycardia, and this finding was reproducible. Questions: What is the mechanism of the observed response? What are the clinical implications?

Unusual case of tachycardia termination: what is the mechanism?

Authors names:

Ahmed T. Moustafa MB BCh, FRCPC¹

Paul Purves CEPS²

George J. Klein MD, FRCPC¹

¹London Heart Rhythm Program, University of Western Ontario, London, ON, Canada.

²Heart Rhythm Program, St. Mary's Hospital, Kitchener, ON, Canada

Corresponding Author:

Ahmed Tarek Moustafa MB BCh

University Hospital

339 Windermere Rd

Room 3C-611B

London

Ontario

N6A 5A5

Canada

+15196633782

Ahmed.Moustafa@lhsc.on.ca

Conflict of interest disclosures:

None reported.

Key words:

orthodromic reciprocating tachycardia

supraventricular tachycardia

ventricular extrastimulus

ablation

Word Count: 727

Case:

A 41-year-old man with no prior cardiac history and a history of regular narrow QRS tachycardia, presenting with frequent paroxysmal palpitations, was referred to our institution. The tachycardia was adenosine-sensitive, leading to the acute termination of the tachycardia. The baseline electrocardiogram was unremarkable. During an electrophysiology study (EPS), supraventricular tachycardia (SVT) was easily induced by ventricular extrastimuli. Figure 1 shows a single ventricular extrastimulus applied from the right ventricular apex (RVa) during the tachycardia, and this finding was reproducible.

Questions:

What is the mechanism of the observed response? What are the clinical implications?

Discussion:

Focusing solely on the surface ECG findings, a deflection consistent with a retrograde P wave is observed at the terminal end of the QRS, although it is challenging to confirm. A very late coupled premature ventricular contraction (PVC) is applied, and it demonstrates evident QRS fusion. This must be by consequence “His refractory”. This PVC delays the subsequent QRS complex. Thus, one observes fusion and reset of the tachycardia, most consistent with macroreentry. The observation suggests that the retrograde limb of the circuit is an accessory pathway (AP).[1] It is worth noting that the ability of a very late coupled PVC from the RV to reset the tachycardia implies that the RV is part of the circuit or has excellent access to it. Possible explanations for this include the presence of a right AP, right paraseptal AP or a right nodoventricular AP.[2, 3]

The intracardiac tracings (Figure 1) reveal that the prevailing SVT is an orthodromic reciprocating tachycardia (ORT), and the retrograde limb is a left lateral AP with eccentric atrial activation.[4] However, this has to be reconciled with the observation that a “very late” coupled PVC from the RV resets and terminates the SVT, making a left lateral AP quite unlikely, as it would require a closer coupled PVC from the RA to access the circuit.

Figure 2 illustrates that the RVa PVC advanced the right atrial electrograms (EGMs) (His A-A 399ms), but not the left atrial EGMs (CS 7-8 A-A 437ms). Simultaneously, it caused a delay in the subsequent QRS and termination of the SVT. This is best explained by a second right AP that did not participate directly in the SVT, as depicted in the schematic diagram (Figure 2).

The cumulative evidence supports the existence of a “double loop” mechanism, in which the anterograde conduction occurs over the normal atrioventricular nodal (AVN) conduction, while retrograde conduction is over either the right or left AP. The left AP circuit activates the atrium ahead of the right AP, preventing the anterograde wave originating from the right AP from conduction into the AVN. However, the right AP still serves as a substrate for the double loop. When the PVC conducts retrogradely over the right AP, it enters the circuit and reveals the right loop. The advanced atrial activation via the right AP subsequently conducts with a long PR interval (HIS A-V 372ms), likely over a slow AVN pathway, and the tachycardia terminates. Consequently, the right AP does not directly participate in the observed SVT (bystander), but

it possesses the capability to reset and terminate it. It is important to note that the tracings do not exclude the possibility of a right nodoventricular connection.

It is speculated that the termination of the tachycardia is due to the effective refractory period (ERP) of the AVN being reached, possibly because of an aborted AVN echo occurring retrogradely over the fast pathway. This renders the fast pathway refractory (retrograde concealed conduction).

After mapping the left lateral AP during RV pacing, radiofrequency ablation was carried out. Subsequent testing confirmed the presence of a right AP with retrograde conduction but without any inducible tachycardia and a long anterograde ERP.

Conclusion:

This case highlights some important clinical implications. In clinical practice, it can be tempting to focus solely on the observed SVT and target the obvious left AP for ablation, without further testing. However, this approach may not be advisable, as it could leave a right AP untouched, leading to the recurrence of an SVT related to it. Conducting a comprehensive diagnostic study does not significantly prolong the procedure and can reveal unexpected findings, such as the presence of a right AP in this case. This underscores the importance of thorough evaluation to ensure all relevant pathways are identified and targeted during ablation, reducing the risk of SVT recurrence.

Figures Legend:

Figure 1. A single ventricular extrastimulus applied from the right ventricular apex (RVa) during the tachycardia. RVa p= Right ventricular apex proximal, HIS d= His bundle distal, HIS p= His bundle proximal, CS= Coronary sinus.

Figure 2. Annotated response to His refractory ventricular extrastimulus and a schematic diagram demonstrating the double loop. Arrows denoting potential retrograde P waves. RVa p= Right ventricular apex proximal, HIS d= His bundle distal HIS p= His bundle proximal, CS= Coronary sinus.

Figures:

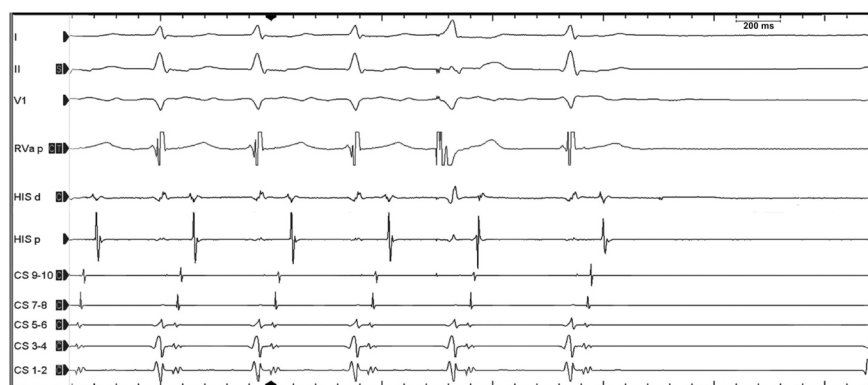

Figure 1. A single ventricular extrastimulus applied from the right ventricular apex (RVa) during the tachycardia. RVa p= Right ventricular apex proximal, HIS d= His bundle distal, HIS p= His bundle proximal, CS= Coronary sinus.

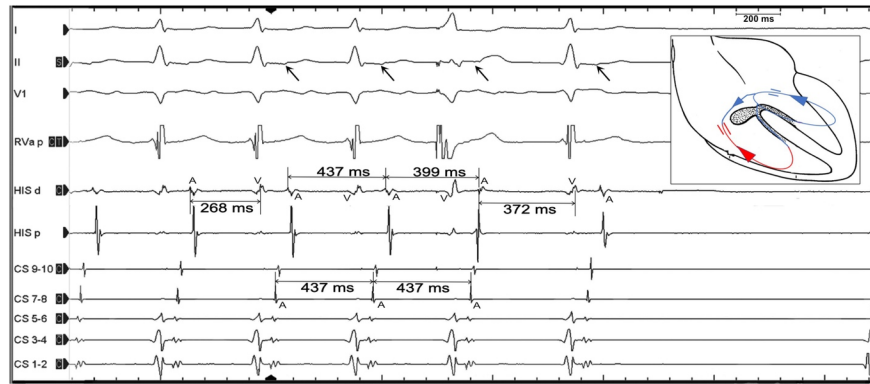


Figure 2. Annotated response to His refractory ventricular extrastimulus and a schematic diagram demonstrating the double loop. Arrows denoting potential retrograde P waves. RVa p= Right ventricular apex proximal, HIS d= His bundle distal HIS p= His bundle proximal, CS= Coronary sinus.

References

1. Veenhuyzen, G.D., et al., *Diagnostic pacing maneuvers for supraventricular tachycardias: part 2. Pacing and clinical electrophysiology*, 2012. **35** (6): p. 757-769.
2. Klein, G.J., et al., *Electrophysiological maneuvers for arrhythmia analysis*. 2014: Cardiotext Publishing.
3. González-Torrecilla, E., et al., *Differences in ventriculoatrial intervals during entrainment and tachycardia: a simpler method for distinguishing paroxysmal supraventricular tachycardia with long ventriculoatrial intervals*. *J Cardiovasc Electrophysiol*, 2011.**22** (8): p. 915-21.
4. Bagga, S., B.J. Padanilam, and E.N. Prystowsky, *Eccentric Atrial Activation During a Narrow QRS Tachycardia: What Is the Mechanism?* *J Cardiovasc Electrophysiol*, 2016. **27** (11): p. 1353-1355.