

Successful treatment of Burkitt lymphoma with metronomic chemotherapy

Pankaj Dwivedi¹, Atul Kapse¹, Chaitali Bongulwar¹, Ankita Tamhane¹, and Sripad Banavali²

¹National Cancer Institute Nagpur

²Tata Memorial Hospital

April 05, 2024

Abstract

Background: Burkitt lymphoma (BL) is an aggressive non-Hodgkin's lymphoma (NHL). With high-dose combination chemotherapy cure rates are excellent but associated with higher rates of infections, and morbidity. Treatment for HIV positive Burkitt lymphoma is similar to HIV negative Burkitt lymphoma along with anti-retroviral therapy. In resource constrained setting offering intensive chemotherapy sometime is difficult. There is scarcity of data regarding use of metronomic chemotherapy in aggressive lymphomas. Results: Here we present outcome and review of literature of child, diagnosed with Burkitt lymphoma and HIV who was treated with metronomic chemotherapy. After year of follow-up he is disease free.

Title: Successful treatment of Burkitt lymphoma with metronomic chemotherapy

Authors and their affiliation:

Pankaj Dwivedi MD^{1*}, Atul Kapse DNB¹, Chaitali Bangurwar MD²Ankita Tamhane MD³, SD Banavali BC⁴

1. Consultant department of pediatric oncology National Cancer Institute Nagpur India
2. Consultant department of nuclear medicine National Cancer Institute Nagpur India
3. Junior consultant department of pathology, National Cancer Institute Nagpur India
4. Professor department of pediatric medical oncology Tata Memorial Centre Mumbai India

*Correspondence: Dr. Pankaj Dwivedi MD Consultant Pediatric Oncology National Cancer Institute Nagpur India.

Contact Number: +917122800400/+919284001655

E-mail address: drpankoo@gmail.com

Word count for Abstract: 124

Main text: 1190

Number of tables: 00

Number of figures: 2

Running title: Burkitt lymphoma treated by metronomic chemotherapy

Key words: Burkitt lymphoma, Metronomic chemotherapy, Non Hodgkin Lymphoma

Abbreviations key

BL	Burkitt lymphoma
NHL	non-Hodgkin's lymphoma
OMCT	Oral metronomic chemotherapy
EFS	Event free survival
OS	Overall survival

Hosted file

abstract_case_report_13sept (1).docx available at <https://authorea.com/users/405623/articles/711804-successful-treatment-of-burkitt-lymphoma-with-metronomic-chemotherapy>

Hosted file

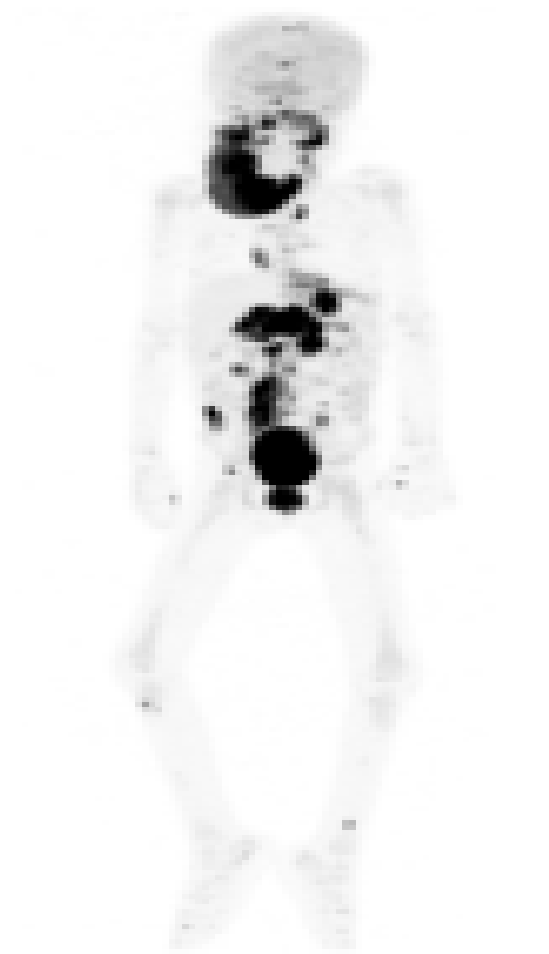case_report_final_(1)_(2) (1).docx available at <https://authorea.com/users/405623/articles/711804-successful-treatment-of-burkitt-lymphoma-with-metronomic-chemotherapy>

Hosted file

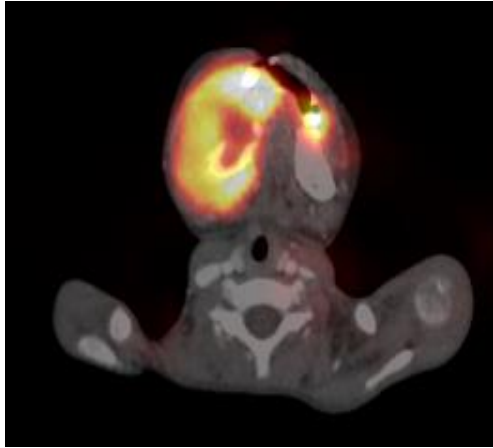
references_case_report_12sept.docx available at <https://authorea.com/users/405623/articles/711804-successful-treatment-of-burkitt-lymphoma-with-metronomic-chemotherapy>

Figure 1 Pre-treatment PET-CT whole body

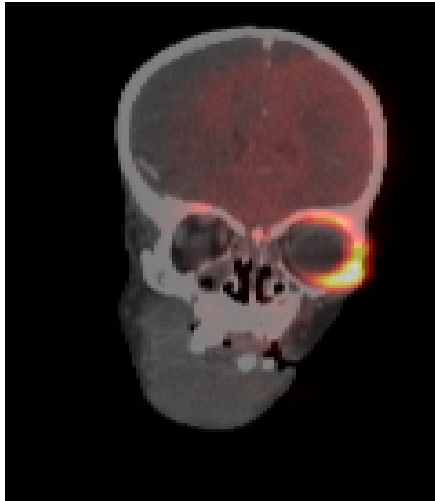
1a



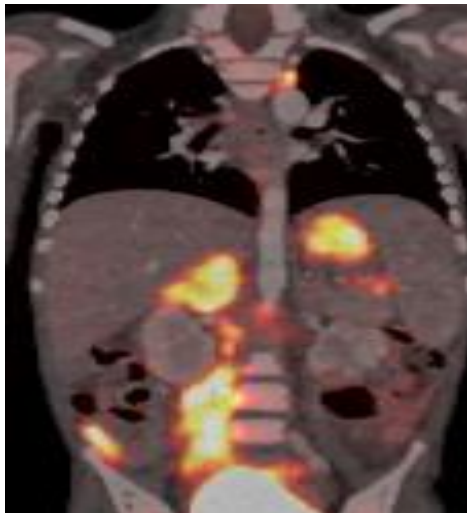
1b



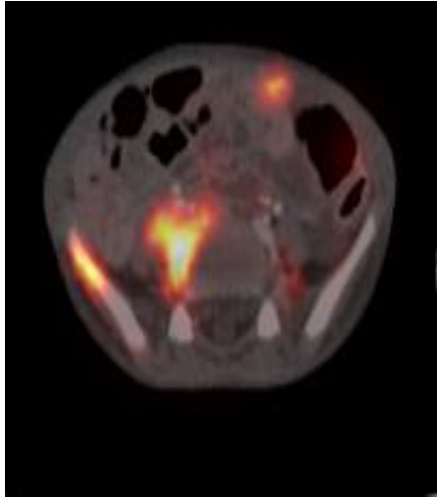
1c



1d



1e



1f

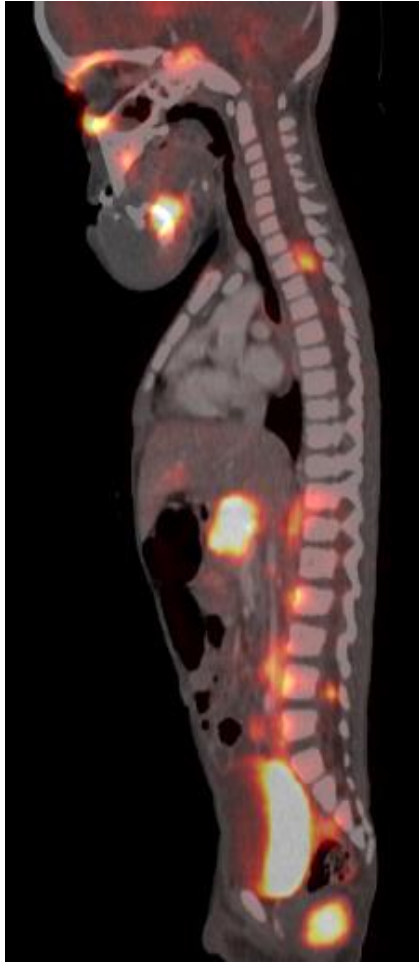
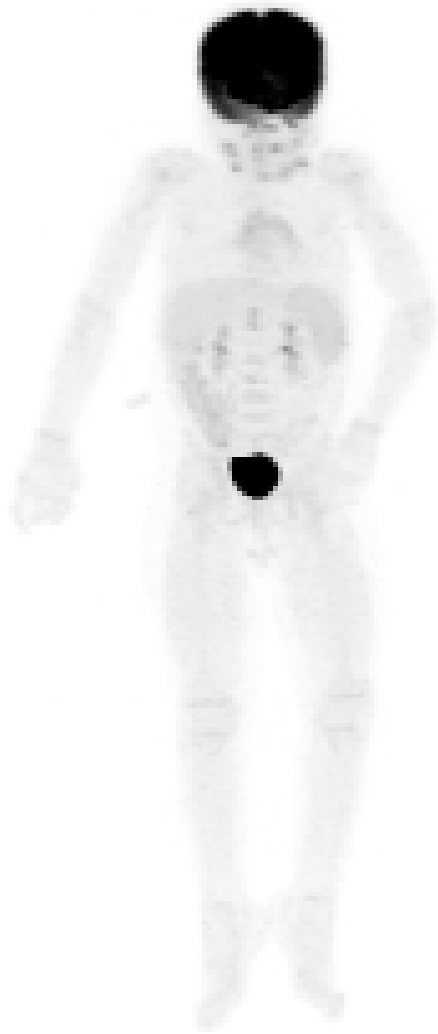
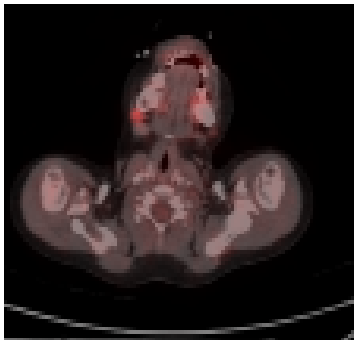


Figure 2 Post treatment PET CT whole body

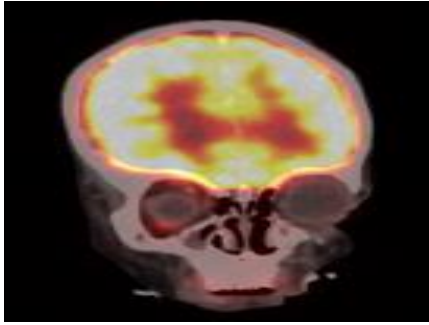
2a



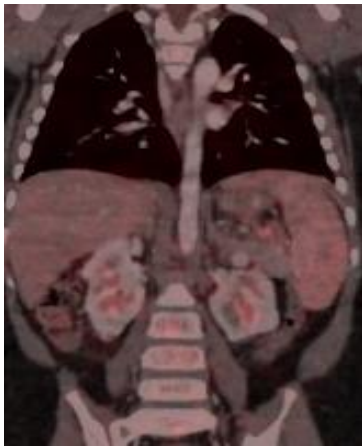2b



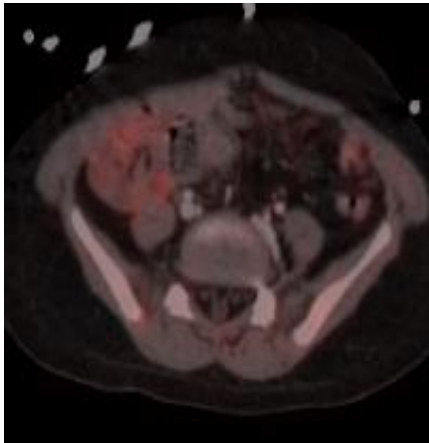
2c



2d



2e



2f

