

Figures

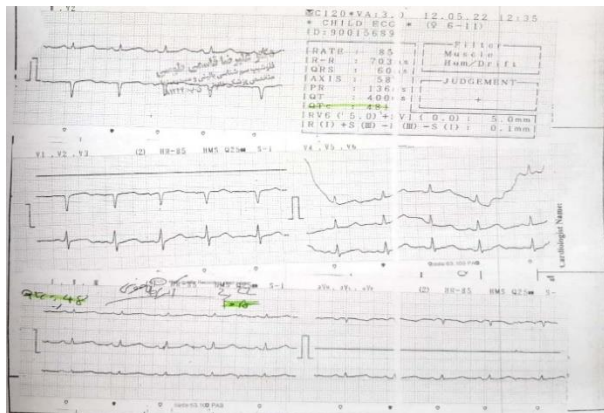


Figure 1: The initial electrocardiogram of a 51-year-old female patient with nortriptyline overdose shows a QTc interval of 481 milliseconds

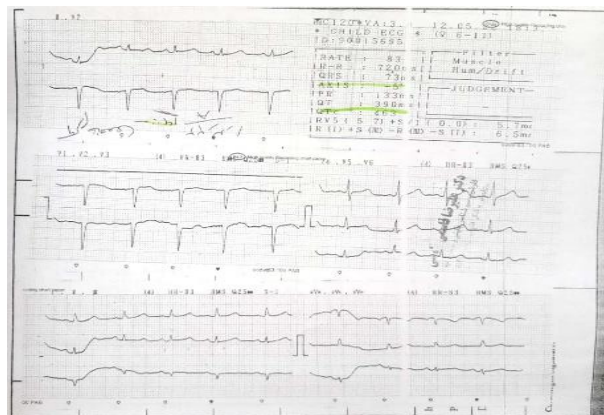


Figure 2: The subsequent electrocardiogram of the same patient after initiation of the therapy, reveals QTc shortening to 463 milliseconds